



Reducing effects of the combination of Methimazole and Propylene glycol Propolis extract on the Bleomycin-induced pulmonary fibrosis

Fatemeh Afzalnia* and Iraj Javadi**

*M.Sc. Student of Toxicology, Department of Toxicology, Shahreza Branch,
Islamic Azad University, Shaahreza, Iran

**Head of the Department of toxicology, Shahreza Branch,
Islamic Azad University, Shaahreza, Iran

(Corresponding author: Iraj Javadi)

(Received 28 September, 2015, Accepted 15 October, 2015)

(Published by Research Trend, Website: www.researchtrend.net)

ABSTRACT: Bleomycin is a useful anti-cancer antibiotics, because, unlike other anti-cancer drugs, it has the least toxic effects on bone marrow cells, so, the blood complications caused by it is minimal. In this study, the combination of Methimazole as an antioxidant and the Propyleneglycol Propolis (PP) extract with strong anti-inflammatory and antioxidant properties was examined. In this experiment, the animal model of adult male Wistar rat was used. Positive control group, negative control group 1 (Normal saline), PG negative control group (Propylene glycol) and combined therapy group, including 80 mg/kg of Methimazole and 50 ml/kg of PP extract, simultaneously received Bleomycin through intraperitoneal injection as a treatment for a period of 7-day pretreatment and for 14 days after endotracheal injection. The amount of Hydroxyproline (OH-Proline) and Malondialdehyde (MDA) in Bleomycin group was respectively 72.8% and 128% more than them in Saline group. The amount of mentioned factors in combined group increased respectively as much as 10% and 4.8%. Also, Histological studies showed that the combined group could control the fibrosis. According to the results, it can be concluded that the administration of Methimazole with PP extract could effectively reduce the pulmonary fibrosis induced by Bleomycin.

Key words: Bleomycin, Pulmonary fibrosis, Methimazole, Propylene glycol Propolis (PP) extract

INTRODUCTION

Bleomycin is a useful anti-cancer antibiotics, because, unlike other anti-cancer drugs, it has the least toxic effects on bone marrow cells, so, the blood complications caused by it is minimal. This outstanding advantage makes it possible that in most cases, this drug can be used in combination with other chemotherapy drugs. Also, it exacerbates the effects of the drugs such as Vinblastine Sulfate and Cisplatin so that administration of them is reduced in the treatment of testicular cancer to one-third. Due to the dangerous and fatal side effect of pulmonary fibrosis, in 10% of the patients treated by Bleomycin, it is observed that 1% of them eventually leads to death. Because of this, its clinical application is faced with a serious problem (Daba *et al.*, 2002). In fact, idiopathic pulmonary fibrosis is a chronic and deadly disease that there is no known cure for it (Johnson *et al.* 2003). The mechanism of the action of Bleomycin is unknown but it is said that after a series of redox reactions related to metal ion (Fe₂) and oxygen, it produces the active oxygen species, especially hydroxyl radical which cause the stranded and double-stranded fractures of DNA and as its result, obvious histological changes are happened in the tissues of the lung (Teixeira *et al.* (2008). Also, another reason that Bleomycin causes the lung injury is the qualitative and quantitative changes of cells in the tissues of the lung, because Bleomycin significantly

increases the number and variety of the inflammatory cell (Sausen *et al.*, (1992). Methimazole is an anti-thyroid. Thyroid hormones play an important role in cell division and setting the basal metabolism of the body. Antioxidants minimize the destructive effects of the free radicals and protect the body cells against the damages caused by these radicals (Martindale the extrapharmacopoeia.london (2014). Methimazole is a strong aggregator of active oxygen radicals and partially restrains the immune system (Usha *et al.*, 2002). Propolis is the product of beehive that the worker bees collect the gum of trees and plants and produce it. Its components includes Resin and Balsams (50-70 %) and pollen (5-10%) and its other ingredients are amino acids, minerals and vitamins A, B complex, E, phenols and aromatic compounds (Drago *et al.*, 2007). Because of phenolic compounds, antioxidant properties of Propolis can be detected. It is likely that two factors which makes antioxidant are PPH (2, 2 diphenyl-1-picrylhydrazyl) and reducing the power of Iron III, this property is better than the antioxidant property of the vitamin C (Benkovic *et al.*, 2009). Flavonoid makes up the bulk of the resin of Propolis that in fact, it is an active component of Propolis and the antioxidant, antibacterial, antifungal, anti-cancer and anti-inflammatory properties of Propolis and its protective effect of the heart are more related to flavonoid and also Propolis can increase the function of immune system due to it (Paulino *et al.*, 2006).

The studied conducted in Iran show that the Propolis, which is available in Iran, has the amount of flavonoids and phenolic compounds (Bankova 2005). Another unique property of this material is its anti-inflammatory property that is due to the inhibition of Prostaglandin production by inhibiting the enzyme of lipoxygenase. Caffeic Acid Phenethyl Ester (CAPE) is the main factor of the properties of Propolis and it is derived from Bioflavonoids and also is easily separable. It can prevent the removal of inflammatory mediators from the mast cells and thereby inhibit the inflammation and allergic reaction (Borrelli *et al.* 2002). The effect of Ethanolicpropolis extract (EEP) on the chronic inflammation was studied by using a mouse which has arthritis. In an animal model of chronic inflammatory, arthritis index was suppressed by EEP (50mg/kg/day and 100 mg/kg/day, P.O). In addition, in the treatment group, the physical weakness, due to the chronic diseases, depending on the dose, improved by EEP. Its analgesic effect was evaluated by Tail-Flick test. It was comparable with the pills of Prednisolone (2.5 mg / kg / day, PO) and Acetylsalicylic acid (100 mg / kg / day, PO). In the test of acute paw edema in rat, which was done to study the effect of EEP's components, it was observed that the component of Petroleum ether (100 mg/kg, PO) is effective in the inhibition of paw edema by using EEP (200 mg/kg, PO) (Lotfy Mohammad. (2006). Propolis can increase the immune mechanisms by influencing on the interferons and increasing the production of antibodies and the activity of phagocytosis (Sforcin 2007). Propolis doesn't solve in water completely due to the wax and resin. According to the research, ethanol is the best solvent to produce the extract of Propolis. This solvent can extract the highest amount of flavonoids from Propolis (Losiane *et al.*, 2013). According to the researches, it has been observed that the antioxidant and anti-inflammatory properties of Propolis is more by the solvent of Propylene glycol (Novak and Sirovina 2013).

The purpose of this study is research on the factors inhibiting the fibrosis to clarify the Bleomycin-induced pulmonary fibrosis mechanism and inhibit it, Because of the uncertainty of Bleomycin-induced pulmonary fibrosis mechanism, will be a significant help in the treatment of cancer patients with no risk of pulmonary fibrosis. Bleomycin-induced pulmonary fibrosis is dependent on the dose and it is the most important factor that makes the prolonged use of this drug challenging. Inhibiting the inflammation and the antioxidant damage to the lungs are the most effective ways to treat lung fibrosis. It is expected that the combination of Methimazole as an antioxidant inhibitor with the anti-inflammatory extract of PP could be an effective treatment of pulmonary fibrosis.

MATERIALS AND METHODS

Bleomycin was prepared from the company of KAYAKU, Japan and the ampoule of etamine, Hydroxyproline, Chloramines T, Para-

Dimethylaminobenzaldehyde, diphenylamine, Thiobarbituric acid, that all of them has analytical purity, were prepared from the company of Merck, Germany.

The male Wistar rats, with the weight of approximately 200-250 gr, were maintained in the animal house for one week at 12 hours of light and 12 hours of darkness, at the temperatures between 20-24 °C and relative humidity of 45-55%. To create an animal model of pulmonary fibrosis of rats were used. Pulmonary toxicity of a single dose of endotracheal bleomycin in rats with pulmonary complications associated with systemic administration of the drug in humans are similar (Kevin *et al.* 2010). After passing adaptation, the rats of each group were weighted and marked. All procedures with animals were done in accordance with the ethic committee for the protection of laboratory animals that was obtained by university faculty including supervisor and university management.

The advantage of endotracheal bleomycin administration to create pulmonary fibrosis is that it creates the fibrotic changes in the lung in a short time. To create pulmonary fibrosis, on the 7th day before treatment, after anesthetizing the animals with Ketamine (50 mg/kg), in negative control group, 30 ml of sterile saline was administered to each animal and in other groups, 30 ml of sterile saline, containing Bleomycin (1IU/Kg) was administered to each animal through endotracheal injection.

To study the anti-inflammatory and antioxidant effects, PP with the dose of 50 mg/kg and 80 mg/kg of Methimazole were selected (Crane 1990, Arabzadesakine., Javadi Iraj 1976).

Propolis was prepared from West Azabaijan Province and until the start of the experiment, it was kept in freezer at -20° C. the extraction was done in accordance with a Cane method (Nada *et al.*, 2012).

First, 10gr of Propolis was grinded, then, 100cc of ethanol 80% added to it. This solution was heated for 3 minutes by magnetic heater and then, it was shaken for 30 minutes. Also, 10gr of Propolis was grinded and poured in 100cc of Propylene glycol 80% and was heated for 3 minutes by magnetic heater and then, it was shaken for 30 minutes. Both sample was kept at ambient temperature for 5 days and then filtrated by Whatman filter paper No.4. The remainder was held in an oven at 30° C for 24 hours. Its dry weight was found, 8.5 gr of Propolis was remained dissolved in a solvent of ethanol and 8 gr of Propolis was remained dissolved in the solvent of Propylene glycol.

Studied groups: In this study, the male rats were randomly divided into separate 4 groups of 6 rats: negative control group 1 and 2, Bleomycin group, combined group. The control group 1 and 2 were administrated by 0.3 ml of sterile saline through endotracheal injection on the 8th day, the solvent of tested drug (sterile saline and Propylene glycol) was administrated to them through intraperitoneal injection.

In pre-treatment period, the sterile saline was administrated to Bleomycin group through intraperitoneal injection and on the 8th day, a dose of Bleomycin (one unit per 100 gr of body weight) in 0.3 ml of sterile saline was administrated to it through endotracheal injection and on following days, it was acted as a control group. In combined group, on the first 7 days (pre-treatment period), 80 mg/kg of Methimazole in 0.3 ml of sterile saline and 50 ml/kg of PP extract were administrated to it through two separate intraperitoneal injections simultaneously and on the 8th day, a dose of Bleomycin (one unit per 100 gr of body weight) in 0.3 ml of sterile saline was administrated to it through endotracheal injection. On following days, it was acted as pre-treatment period.

During the test period, the animals should be considered in terms of general and respiratory status, especially until the 12th day when the animals would face with the respiratory problems. Also, the estate of hair and the loss of it, the daily activities of animal and its consumed food should be considered. The weight of animal is one of the important factors which was measured daily up to fifth day and then it was measured every 4-5 days. This was done by the animal weighing scale. On the final day, the lung was brought out from the chest by cutting the trachea, arteries and other mobile accessories connected to the lungs.

Determining the amount of collagen tissue

To determine the amount of Hydroxyproline which reflects the content of lung's collagen, 0.5 ml of the homogeneous liquid was removed and after the precipitation of its proteins, the sediment was hydrolyzed with normal Chloridric acid 6 at the temperature of 116° C for 18 hours and the amount of Hydroxyproline was measured in accordance with Woessner method (Woessner, 1961.) at the wavelength of 557 nm by spectrophotometer.

The quantification of MDA was carried out by the method of Thiobarbituric acid (TBARS) with the reagent of TBA (Take *et al.*, 2012). Absorption of the samples was read at the wavelength of 532 nm by the spectrophotometer and the amount of MDA was determined. The histology tests were briefly conducted in two stages of cutting and staining. Staining was done by two methods of haematoxylin-eosin and Masson's trichrome strain.

For each group of rats, the mean of the variable was expressed as Mean SEM, and One Way ANOVA was used to compare the means. To determine the difference in means and the significance of the results, Duncan test was conducted by SPSS software. In all tests, p was considered less than 0.05.

RESULTS

Morphological studies of lung showed that in Bleomycin group, the size of lung was significantly increased and severe edema in the lung was visible. Also, the spots of bleeding and fibrosis in the lung were observed. But in negative groups, the lungs were normal and its color was pink and no kinds of edema were observed in the tissue. No spots of bleeding or fibrosis were observed. The mean weight of the lung in the normal saline control group, PG control group, the Bleomycin group and the combined group of Methimazole and PP extract were 1.37 0.63, 1.4 0.81, 2.47 0.12 and 1.36 0.12, respectively. It is observed that there were significant differences between the Bleomycin group and other groups (P 0.05) (Chart1). According to the simultaneous changes in body weight and lung weight, by considering the ratio of lung weight to total body weight,

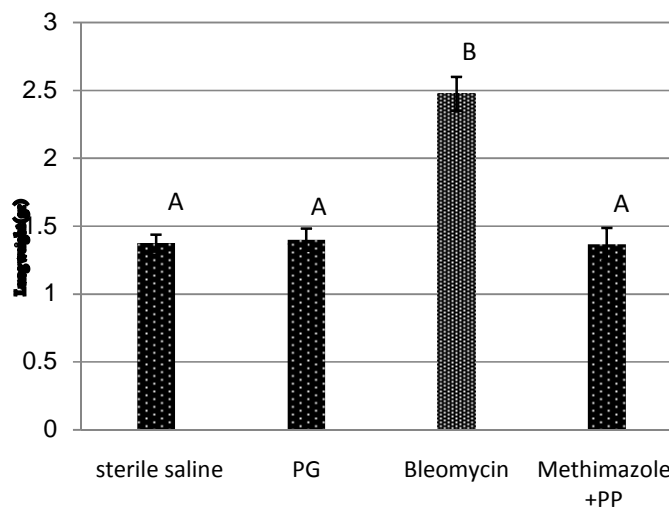
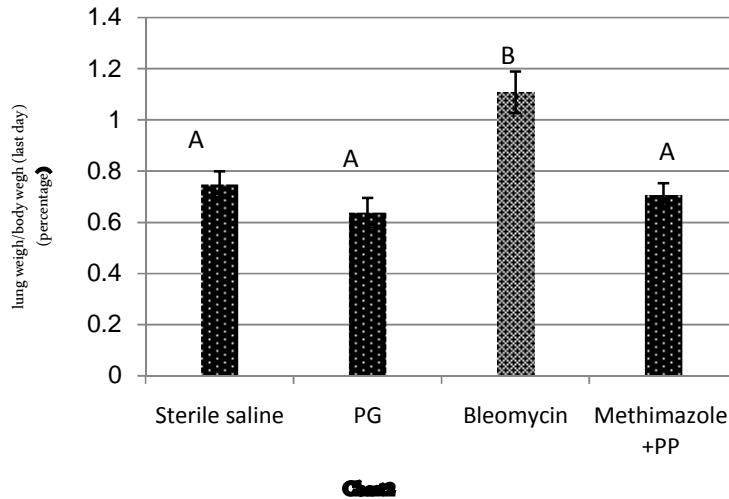


Chart1



it was observed that this ratio in the control group of normal saline, PG control group, the Bleomycin group and the combined group of Methimazole and PP extract were 0.74 0.05, 0.638 0.05, 1.108 0.08 and 0.708 0.04, respectively. It is observed that there were significant differences between the Bleomycin group and other groups (P 0.05). Investigating the ratios, it was observed that in combined group, the ratio was reduced as much as 36.1% compared with the Bleomycin group that it was a significant difference statistically (P 0.05) (Chart 2). In the Bleomycin group, the total amount of pulmonary Malonedialdehyde was increased as much as 128% compared with the normal saline group that it is a significant difference in the analysis of variance (ANOVA) and Duncan's test (P 0.05). In the combined group (Methimazole + PP extract), it was increased as much as 4.8% compared with the negative control group that it was a significant difference statistically.

Also, in combined group (Methimazole + PP extract), it was decreased as much as 54% in compared with the Bleomycin group that it was a significant difference statistically (P 0.05). Investigating the amount of pulmonary Malonedialdehyde, it was obvious that there is no significant differences between the negative control groups and combined group, while there are significant differences between these groups and the positive treatment groups (Chart 3).

Total amount of Hydroxyproline

In the Bleomycin group, the total amount of pulmonary Hydroxyproline was increased as much as 72% in comparison with the control group that it is a significant difference in the analysis of variance (ANOVA) and Duncan's test (P 0.05). In the combined group (Methimazole + PP extract), it was increased as much as 10% compared with the control group.

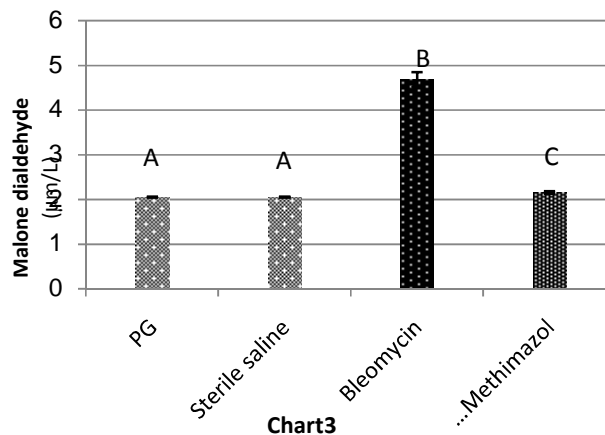


Chart3

Also, the total amount of pulmonary Hydroxyproline in the combined group was decreased as much as 36% in comparison with Bleomycin group that it is a significant difference statistically (P 0.05) (Chart4).

The effect of the combination of Methimazole and PP extract on the lung weight (chart1), the ratio of the lung weight to the body weight on the last day (%)

(chart 2), the amount of Malondialdehyde (chart 4), the amount of pulmonary Hydroxyproline (chart 4) for the studied groups: using One Way ANOVA and Duncan's test, according to Duncan's test (P 0.05), the groups with similar color have the same effects and there are no significant differences between them.

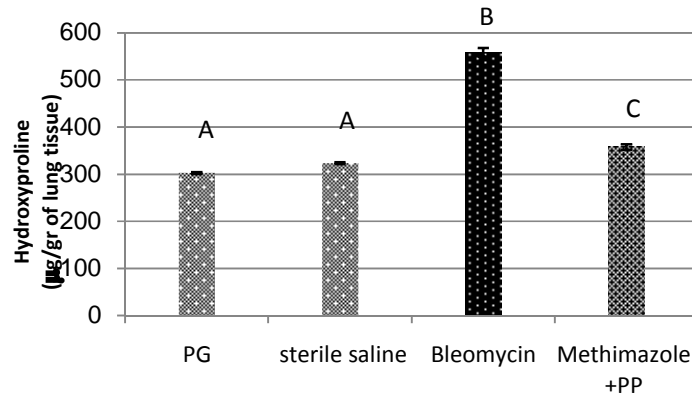


Chart4

The results of histology:

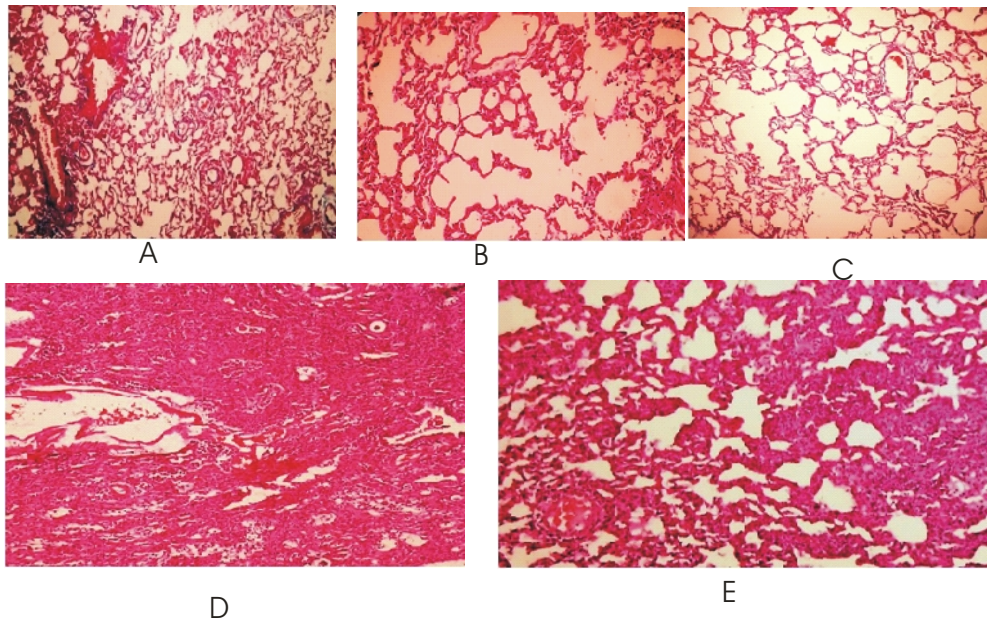


Fig. 1. **A-** Open section of the rat's lung tissue, three weeks after the intraperitoneal injection of normal saline, **B-** Open section of the rat's lung tissue, three weeks after the intraperitoneal injection of Proline glycol, **C-** a sample of normal lung that a dose of 0.3 ml of sterile saline was administrated to it through endotracheal and also it has just received sterile saline through intraperitoneal injection during 21 days of the experiment, it is stained by Masson's trichrome strain. $\times 40$

D- Open section of the rat's lung tissue, two weeks after the endotracheal injection of a dose of Bleomycin, **E-** Open section of the rat's lung tissue, one week before and two weeks after the endotracheal injection of a dose of Bleomycin, the treatment group of Methimazole + PP extract. $\times 40$

DISCUSSION AND CONCLUSION

In this study, it has been shown that the combination of these two substances could reduce the development of pulmonary fibrosis. Pulmonary toxicity of Bleomycin in rats after administrating a dose of Bleomycin through endotracheal injection is similar to the pulmonary complications induced by systemic administration of the drug in human (Kevin *et al.*, 2010). The morphologic changes in the lungs of the animals show that injecting Bleomycin causes the increase of lungweight in Bleomycin and treatment groups in comparison with control group. This increase is due to two reasons: edema and fluid accumulation in the lung tissue that are the consequence of the destruction of alveoli and fluid accumulation in the destructed cavities and another reason is the accumulation of collagen in the lung tissue by fibroblasts (Selman *et al.*, 2001). The increase of the Malonedialdehyde in the rats of positive control group (Bleomycin) is due to the formation and progression of the inflammatory reactions in the lungs (Gao *et al.*, 2012). In the event of inflammatory diseases of the lung, a part of the produced antioxidants in the lungs crosses the cell membranes and enters the bloodstream and in where causes the oxidation of unsaturated fats. According to the results of the measurement of plasma Malonedialdehyde in the groups treated by Methimazole and PP extract, the ingredients of these substances reduced the oxidizing substances in patient rats effectively. The pulmonary fibrosis is caused by the influence of extracellular matrix, sedimentation of the collagen and the proliferation of the cells in interstitial tissue. A high percentage of these cells include fibroblasts and myofibroblasts. These cells increase the synthesis of pulmonary collagen and thus, cause the pulmonary defects (Mango *et al.*, (2008). The amount of Hydroxyprolin represents the amount of collagen in the lungs. Investigating the treatment group, it was observed that it reduced the amount of collagen in the lungs. The photographs of pathology slides related to the positive control group and combined group, showed that the factors released by inflammatory cells (generally, macrophages) cause the inflammatory reactions in the lungs and finally the collapse of alveoli wall and make it thick.

This drug with the used extract with its antioxidant and anti-inflammatory properties have been able to prevent the onset or progression of some reaction and thus, have reduced the rate of the progression of fibrosis. According to the results of this study, it can be suggested that Methimazole with PropyleneglycolPropolis(PP) extract can be used in different and higher doses, the better results may be achieved.

FURTHER STUDY

This study can contribute to future research on effects of antioxidant and anti-inflammatory properties and reduce the Bleomycin-induced pulmonary fibrosis for helping to Patients with cancer.

ACKNOWLEDGMENTS

My spatial thanks to the faculty at Islamic Azad University of Shaahreza for their endless support.

ABBREVIATIONS

PP extract: Propylene glycol Propolis extract

PG: Propylene glycol

OH-Proline: Hydroxyproline

MDA: Malonedialdehyde

CAPE : Caffeic Acid Phenethyl Ester

EPP: Ethanolic propolis extract

REFERENCES

- Daba MH., Abdel-Aziz AH., Moustafa AM., Al-Majed AA., Al-Shabanah OA., El-Kashef HA. (2002). Effects of L-Carnitin and Ginkgo Biloba Extract (EG b 761) in Experimental Bleomycin-Induced Lung Fibrosis. *Pharmacol Res.* **45**(6): 461- 467.
- Johnson BJ ,ET AL., (2003). Statin use is associated with improved function and survival of lung allografts. **167**: 127.
- Teixeira KC., Soares FS., Rocha LG., Silveira PC., Silva LA., Valença SS, et al. (2008). Attenuation of Bleomycin-Induced Lung Injury and Oxidative Stress by N-Acetylcysteine Plus Deferoxamine. *Pulm Pharmacol Ther.* **21**(2):309316.
- Sausen PJ., Elfarrar AA., Cooley AJ., (1992). Methimazole protection of rats against chemically induced kidney damage in vivo. *J.Pharm. Exp.* **260**(1): 393-401.
- Martindale the extrapharmacopoeia.london (2014): *Royal pharmaceutical society.* 2014; **38**: 1372-1373.
- Usha R Deshpande., Lehana J Joseph., Uma N Patwardhan & Aban M Samuel. (2002). Effect of antioxidants (vitamin C, E and turmeric extract) on methimazole induced hypothyroidism in rats. *Radiation Medicine Centre; Indian J Exp Biol.* **40**(6): 735-8.
- Drago L ., Devecchi E, Nicola L., Gismond MR. (2007). In vitro antimicrobial activity of a novel propolis formulation (Actichelated propolis). **103**: 1914-1921.
- Benkovic V., Knezevic AH., Dikic D, Lisicic D., Orsolic N., Basic I, (2009). Radioprotective effects of quercetin and ethanolic extract of propolis in gamma-irradiated mice. **60**: 129-138.
- Paulino N., Teixeira C., Martins R., Scremin A., Dirsch VM., Vollmar AM., Abreu SR . (2006). Evaluation of the analgesic and antiinflammatory effects of a Brazilian green propolis. *Planta Med.* **72** (10): 899-906.
- Bankova V., (2005). Chemical diversity of propolis and the problem of standardization. *J Ethnopharmacol.* 2005; **100**: 114-117.
- Borrelli F., Maffia P., Pinto L., Ianaro A., Russo A, Capasso F., et al. (2002). Phytochemical compounds involved in the anti-inflammatory effect of propolis extract. *Fitoterapia.* **73**(1): 53-63.

- Lotfy Mohammad. (2006). Biological Activity of Bee Propolis in Health and Disease. *Asian Pacific Journal of Cancer Prevention*. 7.
- Sforzin JM., (2007). Propolis and the immunesystem. *J Ethnopharmacol*. 2007; **113**(1): 1-14.
- Losiane C. Paviani., Giulia Fiorito., Patricia Sacoda., Fernando A. (2013). Different Solvents For Extraction of Brazilian Green Propolis. *IIIberoamerican Conference on Supercritical Fluids Cartagena de Indias (Colombia)*.
- Novak., S, Sirovina. (2013). Antioxidative and anti-inflammatory activity of Croatian propolis preparations in alloxan induced diabetes in mice:302.
- Kevin M. Vannella., Tracy R. Luckhardt., Carol A. Wilke., Linda F. van Dyk., Galen B. Toews., and Bethany B. Moore. (2010). *Latent Herpesvirus Infection Augments Experimental Pulmonary Fibrosis*. **181**(5): 465-477.
- Crane . (1990). *Bees and Beekeeping: Science, Practice and World Resources*. Cornell University Press, Ithaca, NY.
- Arabzadesakine., Javadi Iraj. The effect of Methimazole on the Bleomycin-induced pulmonary fibrosis in rat models., PhD thesis. university of Isfahan. 1376.
- Nada - Nada Oršoli I, Damir Sirovina, Marijana Zovko Kon i, Gordana Lackovi and Gordana Gregorovi . (2012). Effect of Croatian propolis on diabetic nephropathy and liver toxicity in mice. *BMC Complementary and Alternative Medicine* **12**: 117.
- Woessner JF. (1961). The determination of hydroxyproline in tissue and protein samples containing small proportions of amino acid. *Drch. Biochem. Biophys*. **93**: 440-447.
- Take T., Maddane E Kiyici A., (2012). Cigarette Smoke and Bleomycin-induced Pulmonary and Therapeutic Medicine. *Exp Ther Med*. **4**:121-124.
- Kevin M. Vannella., Tracy R. Luckhardt., Carol A. Wilke., Linda F. van Dyk., Galen B. Toews., and Bethany B. Moore. (2010). *Latent Herpesvirus Infection Augments Experimental Pulmonary Fibrosis*. **181**(5): 465-477.
- Selman M., King TE., Pardo A. 2001. Idiopathic Pulmonary Fibrosis: Prevailing and Evolving Hypotheses about Its Pathogenesis and Implication for Therapy. **134**(2):136-151.
- Gao Y., Zhao J., Fu Y, Liang L., Luo M., Wang W., Efferth T. (2012). Antioxidant Properties, superoxide dismutase and glutathione reductase activities in HePG2 cell with a fungal endophyte producing apigenin from pigeon pea . *Food Res Int*. **49**:147-152.
- Mango ED, et al., (2008). Activation of NF- κ B by adherent *Pseudomonas aeruginosa* in normal and cystic fibrosis respiratory epithelial cells. **2008**; **101**(11): 2598-2605.