

## Histomorphometric Studies on Mammary Gland of Barbari Goat in Eastern Uttar Pradesh

Nripendra Singh<sup>1</sup>, Mukesh Kumar<sup>1</sup>, Krishna Nand Singh<sup>1</sup>, Debaish Niyogi<sup>2</sup>, Rakesh Kumar Gupta<sup>2\*</sup> and Amit Singh Visen<sup>3</sup> and Kabir Alam<sup>4</sup>

<sup>1</sup>Department of Veterinary Anatomy & Histology, C.V.Sc. & A.H., ANDUAT, Kumarganj, Ayodhya (Uttar Pradesh), India.

<sup>2</sup>Department of Veterinary Pathology, C.V.Sc. & A.H., ANDUAT, Kumarganj, Ayodhya (Uttar Pradesh), India.

<sup>3</sup>Department of Veterinary Anatomy, C.O.V.A.Sc., GBPUAT, Pantnagar, Uttarakhand, India.

<sup>4</sup>Department of Veterinary Gynaecology & Obstetrics, C.V.Sc. & A.H., ANDUAT, Kumarganj, Ayodhya (Uttar Pradesh), India.

(Corresponding author: Rakesh Kumar Gupta\*)

(Received 14 September 2022, Accepted 28 October, 2022)

(Published by Research Trend, Website: [www.researchtrend.net](http://www.researchtrend.net))

**ABSTRACT:** Present study was conducted to explore the histomorphometry of mammary gland in Barbari goat in Eastern Uttar Pradesh. The investigation was carried out for the various components of the 24 mammary glands of barbari goat. Microscopic images were captured using the Lieca microscope (CH9345 Heerbrugg). The average diameter of alveoli in Barbari goat ranged from 22.10 to 37.15  $\mu\text{m}$ . The average of it was  $30.34 \pm 0.91$ . The diameter of lobules in Barbari goats ranged from 0.10 to 0.71 mm and the average of it was  $0.29 \pm 0.04$  mm. The number of alveoli per lobule/1  $\text{cm}^2$  in Barbari goat ranged from 526 to 860 and the average of it was  $658.70 \pm 18.39$  per lobule/cm. The height of alveolar epithelium ( $\mu\text{m}$ ) in Barbari goat ranged from 3.02 to 10.60  $\mu\text{m}$  and the average of it was  $6.58 \pm 0.42$ . The width of alveolar epithelium ( $\mu\text{m}$ ) in Barbari goat ranged from 4.08 to 12.12  $\mu\text{m}$  and the average of it was  $8.16 \pm 0.51$   $\mu\text{m}$ . The diameter of alveolar epithelium in Barbari goat ranged from 0.24 to 0.62  $\mu\text{m}$  and the average of it was  $0.48 \pm 0.03$   $\mu\text{m}$ . The diameter of inter-lobular duct in Barbari goat ranged from 58 to 86  $\mu\text{m}$  and the average of it was  $72 \pm 1.85$   $\mu\text{m}$ . The diameter of intra-lobular duct in Barbari goat ranged from 32 to 62  $\mu\text{m}$  and the average of it was  $44.70 \pm 2.15$   $\mu\text{m}$  respectively.

**Keywords:** Mammary gland, Barbari goat, Histomorphometry, Eastern Uttar Pradesh.

### INTRODUCTION

In dairy industry, the importance of small ruminants has increased in recent years, especially in developing countries, where it has high social and economic impacts (Lerias *et al.*, 2014; Mohanty *et al.*, 2020; Sharma *et al.*, 2022). Goat has been described as Poor Man's Cow because of its immense contribution in ensuring food and nutritional security. Barbari is a dual purpose (Milk and Meat) goat breed and also known as "Dwarf Guinea Goat" (Jindal, 1984). The udder in goat comprised of two mammary glands located between the thighs and each gland drained into a single well-defined teat which is made up of teat cistern, teat wall, Furstenberg's rosette and teat canal (Mahdi, 2009). The

number of cells per alveoli increases as the cycle proceeded from pregnancy in barbari goat.

The diameter of smaller alveoli ranges from  $0.414 \times 10^3$  to  $1.490 \times 10^3$   $\mu\text{m}$  (Mehta, 2013; Senthilkumar *et al.*, 2020). The average number of alveoli per lobule is 254.77 in pregnant goat (Paramasivan and Geetha 2014; Senthilkumar *et al.*, 2020). The height of alveoli in lactating and non-lactating goat ranges from 14.10 to 18.1  $\mu\text{m}$  and 4.02 to 10.61  $\mu\text{m}$  respectively (Shivprasad, 2018; Senthilkumar *et al.*, 2020). Various authors have elaborated about the histomorphometry of mammary gland in goat but data on Barbari goat in eastern Uttar Pradesh is not much in literature. Therefore, present study was conducted to explore the histomorphometry of mammary gland in Barbari goat.

## MATERIAL AND METHODS

20 mammary gland samples from adult barbari goat were collected from Fair Export Pvt. Ltd. Barabanki, U.P. and 4 mammary gland samples were collected from Postmortem house, Department of Veterinary Pathology brought for postmortem examination. Then tissue sample were directly fixed in 10 percent neutral buffered formalin and Bouin's fluid. The tissue processing and staining were carried out in the Department of Veterinary Anatomy and Histology, College of Veterinary Science and Animal Husbandry, Acharya Narendra Deva University of Agriculture and Technology, Kumarganj, Ayodhya-224229 (U.P.). Collected tissue were processed by routine alcohol-xylene schedule and paraffin blocks were made (Luna, 1968). Sections were cut at 5-7  $\mu\text{m}$  thickness and stained by haematoxylin and eosin method for the routine histological study (Bancroft and Gamble 2003). Microscopic images were captured using the Leica microscope (CH9345 Heerbrugg). Micrometry was

done using the Leica application suite (LAS V4.4) (Kannan *et al.*, 2019) for following parameters:

1. Diameter of alveoli measured in ( $\mu\text{m}$ )
2. Diameter of lobule measured in (mm)
3. Number of alveoli per lobule measured in ( $\text{mm}^3$ )
4. Diameter of alveolar lumen measured in ( $\mu\text{m}$ )
5. Height of alveolar epithelium measured in ( $\mu\text{m}$ )
6. Width of alveolar epithelium measured in ( $\mu\text{m}$ )
7. Diameter of nuclei measured in ( $\mu\text{m}$ )
8. Diameter of inter-lobular duct measured in ( $\mu\text{m}$ )
9. Diameter of intra-lobular duct measured in ( $\mu\text{m}$ )

**Statistical analysis:** Statistical analysis of data was done by using SPSS 20 software.

## RESULT AND DISCUSSION

The micrometrical observation for the different parameters was measured by averaging 4 to 5 fields from each prepared slide and subjected to statistical analysis by using SPSS 20 software and represented in Table 1 and 2.

**Table 1: Micrometrical observation of the various parameter of the Mammary gland of Barbari goat.**

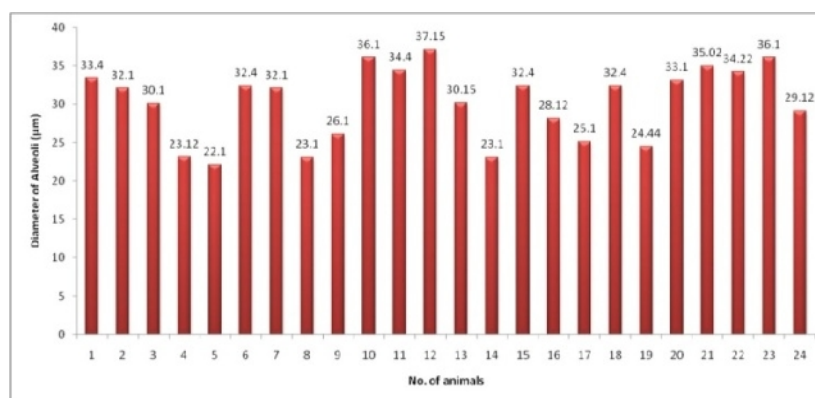
Sr. No.	Diameter of Alveoli ( $\mu\text{m}$ )	Diameter of Lobule (mm)	No. of Alveoli per lobules/ $\text{cm}^3$	Average Diameter of Alveolar lumen ( $\mu\text{m}$ )	Height of Alveolar Epithelium ( $\mu\text{m}$ )	Width of Alveolar Epithelium ( $\mu\text{m}$ )	Diameter of Alveolar Epithelium ( $\mu\text{m}$ )	Average Diameter of Inter lobular duct ( $\mu\text{m}$ )	Average Diameter of Intra lobular duct ( $\mu\text{m}$ )
1.	33.40	0.71	712	0.50	8.20	12.10	0.35	70	36
2.	32.10	0.14	655	0.90	8.24	5.45	0.62	60	41
3.	30.10	0.11	775	0.92	7.10	5.20	0.30	80	37
4.	23.12	0.20	610	0.80	4.10	10.12	0.60	80	38
5.	22.10	0.21	720	0.90	4.32	9.25	0.63	85	35
6.	32.40	0.28	675	1.05	7.00	11.12	0.25	60	32
7.	32.10	0.38	612	03	8.11	10.14	0.30	74	60
8.	23.10	0.12	625	0.80	6.12	5.75	0.55	60	42
9.	26.10	0.10	528	0.89	5.00	5.22	0.70	62	35
10.	36.10	0.77	621	0.90	7.12	9.12	0.70	68	62
11.	34.40	0.52	780	0.95	8.00	12.12	0.27	75	32
12.	37.15	0.23	728	0.90	10.02	9.10	0.30	85	60
13.	30.15	0.20	528	0.80	10.60	11.20	0.62	65	61
14.	23.10	0.70	612	0.12	3.02	7.22	0.62	75	42
15.	32.40	0.16	655	0.90	3.15	10.10	0.58	82	58
16.	28.12	0.20	528	0.94	4.08	10.08	0.60	68	38
17.	25.10	0.65	526	1.08	9.22	10.12	0.24	85	38
18.	32.40	0.20	620	0.90	7.05	10.10	0.28	65	34
19.	24.44	0.22	720	0.70	5.08	6.38	0.50	80	38
20.	33.10	0.11	611	1.45	6.11	6.22	0.52	58	48
21.	35.02	0.23	820	0.91	5.30	5.40	0.42	65	60
22.	34.22	0.12	610	0.95	9.20	4.08	0.62	86	43
23.	36.10	0.13	678	1.34	5.20	5.22	0.48	65	60
24.	29.12	0.28	860	1.32	6.65	5.23	0.52	75	43

**Table 2: Statistical analysis of micrometrical observation of various parameters of Mammary gland of Barbari goat.**

Sr. No.	Parameters	Minimum	Maximum	Mean $\pm$ SE	S.D.	C.V.
1.	Diameter of Alveoli ( $\mu\text{m}$ )	22.10	37.15	30.34 $\pm$ 0.91	4.46	14.72
2.	Diameter of Lobule (mm)	0.10	0.77	0.29 $\pm$ 0.04	0.20	71.68
3.	No. of Alveoli per lobules/1 $\text{cm}^3$	526	860	658.70 $\pm$ 18.39	90.11	13.68
4.	Average Diameter of Alveolar lumen ( $\mu\text{m}$ )	0.12	1.45	0.91 $\pm$ 0.05	0.25	28.09
5.	Height of Alveolar Epithelium ( $\mu\text{m}$ )	03.02	10.60	6.58 $\pm$ 0.42	2.07	31.5
6.	Width of Alveolar Epithelium ( $\mu\text{m}$ )	04.08	12.12	8.16 $\pm$ 0.51	2.54	31.10
7.	Diameter of Alveolar Epithelium ( $\mu\text{m}$ )	0.24	0.62	0.48 $\pm$ 0.03	0.15	31.60
8.	Average Diameter of Inter lobular duct ( $\mu\text{m}$ )	58	86	72 $\pm$ 1.85	9.09	12.63
9.	Average Diameter of Intra lobular duct ( $\mu\text{m}$ )	32	62	44.70 $\pm$ 2.15	10.53	23.56

**1. Average Diameter of Alveoli ( $\mu\text{m}$ ).** The diameter of alveoli in Barbari goat ranged from 22.10 to 37.15  $\mu\text{m}$  (Fig. 1). The average of it was 30.34  $\pm$  0.91. These observations are in accordance with the finding of Shivprasad (2018) in lactating and non-lactating goat ranged from 108.01 to 132.01  $\mu\text{m}$  and 25.01 to 38.12  $\mu\text{m}$  respectively. The average of it was 117.71  $\pm$  0.96

and 33.69  $\pm$  0.38  $\mu\text{m}$ . The average values of diameter of alveoli showed significant difference between lactating and non-lactating stages. Mehta (2013) and Senthilkumar *et al.* (2020) also observed diameter of smaller alveoli ranged from  $0.414 \times 10^3$  to  $1.490 \times 10^3$   $\mu\text{m}$  in different stages of hormonal induction. Jacobson (2000) also observed diameter of alveoli was 200  $\mu\text{m}$ .



**Fig. 1.** Histogram showing average diameter of alveoli ( $\mu\text{m}$ ).

**2. Average Diameter of Lobules (mm).** The diameter of lobules in Barbari goats ranged from 0.10 to 0.71 mm (Fig. 2) and the average of it was 0.29  $\pm$  0.04 mm. These findings are consistence with those of Sulochana *et al.* (1981a); Senthilkumar *et al.* (2020) who measured lobules in goats that were 0.5 to 1.5 mm long and 0.5 mm wide. Bhatia and Sahai (1979) found that in lactating and non-lactating buffaloes recorded the average number of alveoli was 70.5 and 24.52 mm in per field of the microscope. Kausar *et al.* (2001) in dromedaries. Shivprasad (2018) in sheep and goat even reported the similar finding.

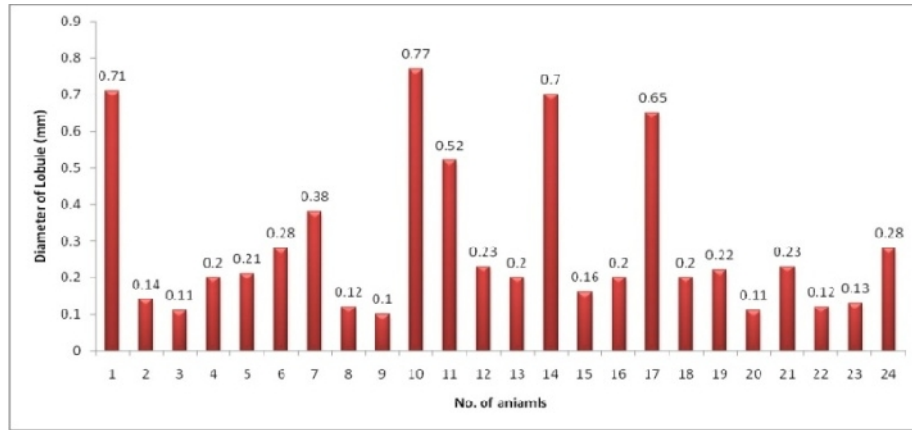
**3. Number of alveoli per lobule/1  $\text{cm}^2$ .** The number of alveoli per lobule/1  $\text{cm}^2$  in Barbari goat ranged from

526 to 860 (Fig. 3) and the average of it was 658.70  $\pm$  18.39 per lobule/ $\text{cm}^2$ . Similar findings were observed by Shivprasad (2018) in lactating and non-lactating goat ranged from 1108 to 2315 and 510 to 860 respectively. The average of it was 1616.57  $\pm$  76.79 and 664.80  $\pm$  15.81 per lobule/ $\text{cm}^2$ . Sulochana *et al.* (1981); Senthilkumar *et al.* (2020) observed that in an active lobule the number of alveoli ranged from 100 to 300 depending on the size of lobule and reproductive condition of the animal. These observation corroborates with that of Naik (2015) in mammary gland of malnadgidda breed of cow that the number of alveoli per lobule was 116.4  $\pm$  5.97  $\mu\text{m}$ . Paramasivan and Geetha (2014) also observed the number of alveoli per

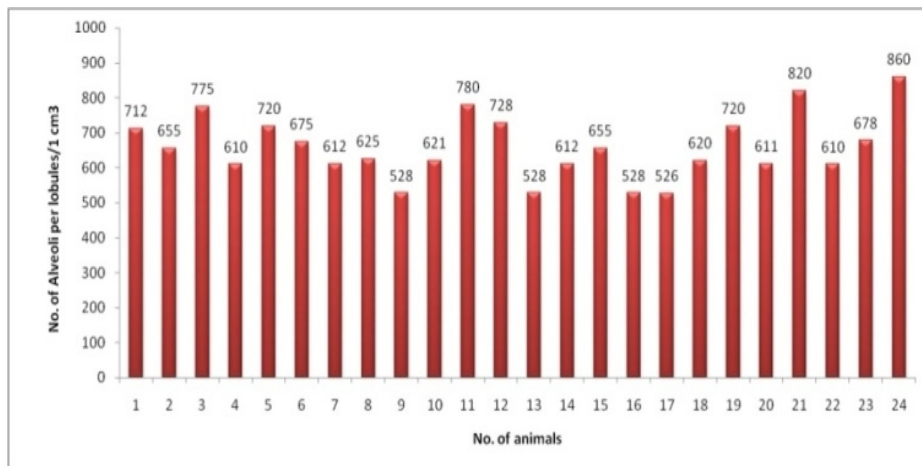
lobule was  $254.77 \pm 14.96$  in pregnant animals which reduced significantly to  $108.27 \pm 15.64$  during lactating animals.

**4. Average diameter of alveolar lumen ( $\mu\text{m}$ ).** The diameter of alveolar lumen ( $\mu\text{m}$ ) in Barbari goat ranged from 0.12 to 1.45  $\mu\text{m}$  (Fig. 4) and the average of it was  $0.91 \pm 0.05 \mu\text{m}$ . These result corroborates with the findings of Shivprasad (2018); Senthilkumar *et al.*

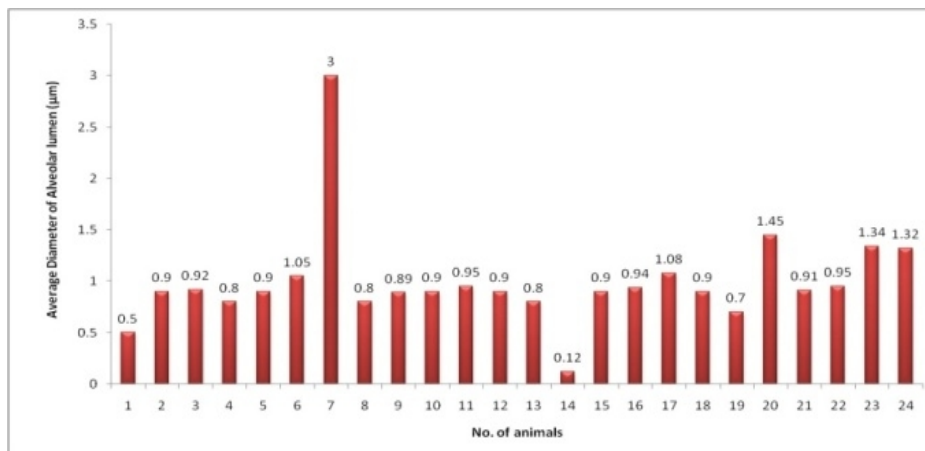
(2020) in lactating and nonlactating goat ranged from 0.98 to 1.52  $\mu\text{m}$  and 0.52 to 1.46  $\mu\text{m}$  respectively. The average of alveolar lumen was  $1.20 \pm 0.03$  and  $0.94 \pm 0.02 \mu\text{m}$ . The average diameter of alveolar lumen showed significant difference between lactating and non-lactating stages. The average diameter of alveolar lumen ( $\mu\text{m}$ ) in Barbari goat ranged from 0.12 to 1.45  $\mu\text{m}$  and the average of it was  $0.91 \pm 0.05 \mu\text{m}$ .



**Fig. 2.** Histogram showing average diameter of lobules(mm).



**Fig. 3.** Histogram showing number of alveoli per lobule/1 cubic cm<sup>2</sup>.



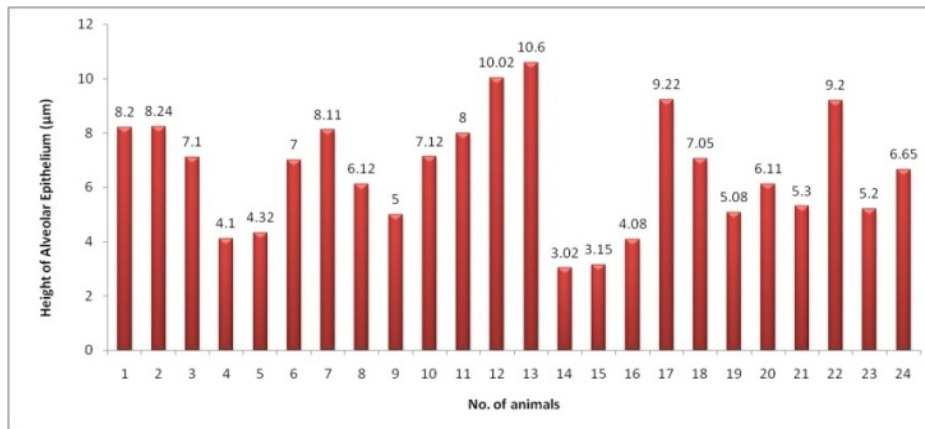
**Fig. 4.** Showing average diameter of alveolar lumen ( $\mu\text{m}$ ).

**5. Height of alveolar epithelium ( $\mu\text{m}$ ).** The height of alveolar epithelium ( $\mu\text{m}$ ) in Barbari goat ranged from 3.02 to 10.60  $\mu\text{m}$  (Fig. 5) and the average of it was  $6.58 \pm 0.42$ . The average height of alveolar cells was more in active gland than in less active gland. The epithelium height of intra-lobular ducts varied significantly in the mammary gland of different stage in goat. These result corroborates with the findings of Shivprasad (2018); Senthilkumar *et al.* (2020) in lactating and non-lactating goat ranged from 14.10 to 18.1  $\mu\text{m}$  and 4.02 to 10.61  $\mu\text{m}$  respectively. The average of it was  $16.27 \pm 0.12 \mu\text{m}$  and  $7.26 \pm 0.26 \mu\text{m}$ .

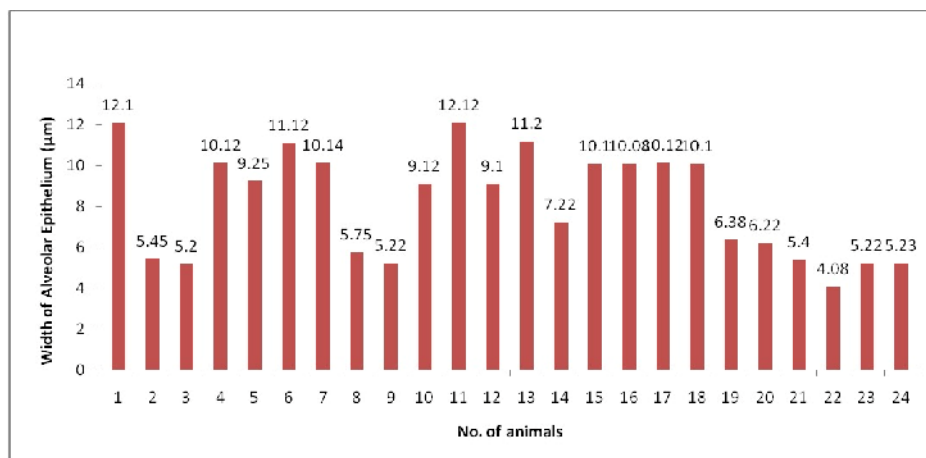
**6. Width of alveolar epithelium ( $\mu\text{m}$ ).** The width of alveolar epithelium ( $\mu\text{m}$ ) in Barbari goat ranged from 4.08 to 12.12  $\mu\text{m}$  (Fig. 6) and the average of it was  $8.16 \pm 0.51 \mu\text{m}$ . These result corroborates with the findings of Shivprasad (2018); Senthilkumar *et al.* (2020) in lactating and non-lactating goat ranged from 13.11 to 34.43  $\mu\text{m}$  and 4.09 to 12.12  $\mu\text{m}$  respectively. The average of it was  $23.85 \pm 1.18$  and  $7.71 \pm 0.39 \mu\text{m}$ . Width of alveolar epithelium in lactating stage was significantly more than that measured in non-lactating stage. The average values of width of alveolar epithelium showed significant difference between lactating and non-lactating stages.

**7. Diameter of Alveolar Epithelium ( $\mu\text{m}$ ).** The diameter of alveolar epithelium in Barbari goat ranged from 0.24 to 0.62  $\mu\text{m}$  (Fig. 7) and the average of it was  $0.48 \pm 0.03 \mu\text{m}$ . These result corroborates with the findings of Shivprasad (2018); Senthilkumar *et al.* (2020) in lactating and non-lactating goat ranged from 0.92 to 1.18  $\mu\text{m}$  and 0.26 to 0.81  $\mu\text{m}$  respectively. The average of it was  $1.07 \pm 0.01$  and  $0.51 \pm 0.02 \mu\text{m}$ . The average values of diameter of alveolar epithelium showed significant difference between lactating and non-lactating stages.

**8. Average diameter of inter-lobular duct ( $\mu\text{m}$ ).** The diameter of inter-lobular duct in Barbari goat ranged from 58 to 86  $\mu\text{m}$  (Fig. 8) and the average of it was  $72 \pm 1.85 \mu\text{m}$ . Similar observations are reported by Shivprasad (2018); Senthilkumar *et al.* (2020) in lactating and non-lactating goat ranged from 108 to 267  $\mu\text{m}$  and 61 to 89  $\mu\text{m}$ . The average of it was  $158.30 \pm 5.21$  and  $71.50 \pm 1.41 \mu\text{m}$ . The average values of diameter of inter lobular duct showed significant difference between lactating and non-lactating stages. Senthilkumar *et al.* (2020) also observed diameter of intra-lobular ducts was 35 to 42  $\mu\text{m}$  and 5-90  $\mu\text{m}$  in parturient and ten months lactating cow.



**Fig. 5.** Showing height of alveolar epithelium ( $\mu\text{m}$ ).



**Fig. 6.** Showing width of alveolar epithelium ( $\mu\text{m}$ ).



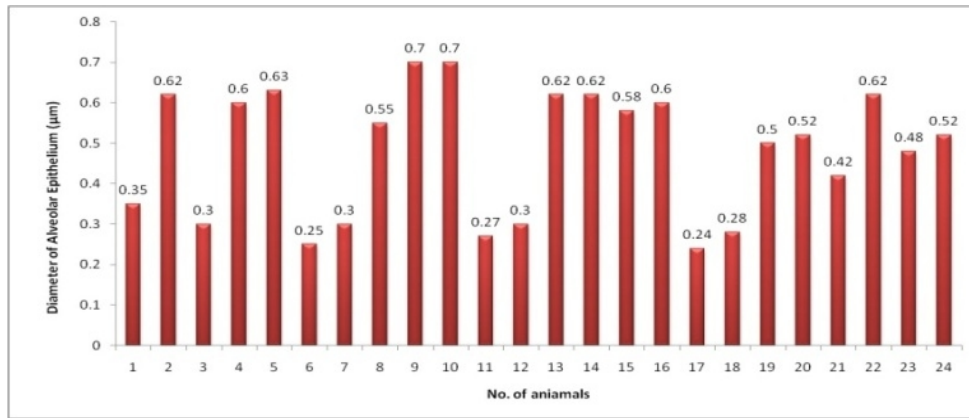


Fig. 7. Showing diameter of alveolar epithelium (µm).

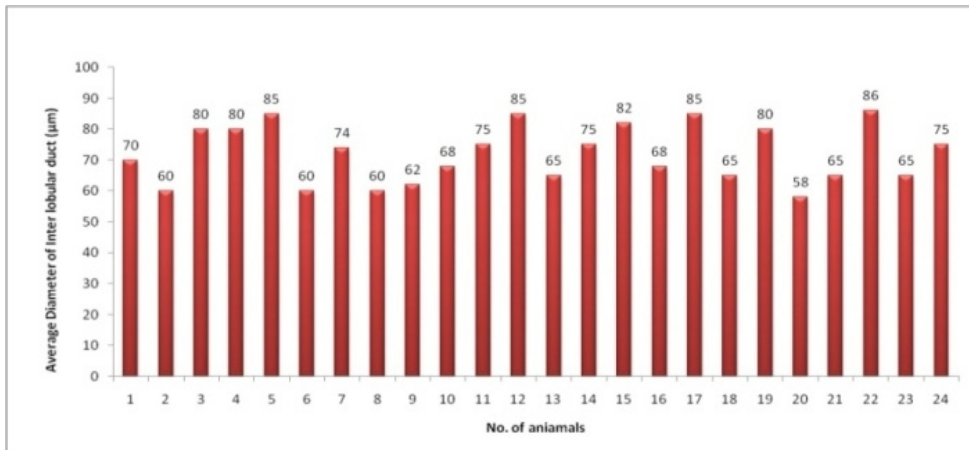


Fig. 8. Showing average diameter of inter-lobular duct (µm).

**9. Average diameter of intra-lobular duct (µm).** The average diameter of intra-lobular duct in Barbari goat ranged from 32 to 62 µm (Fig. 9) and the average of it was  $44.70 \pm 2.15$  µm respectively. Similar observations are reported by Shivprasad (2018); Senthilkumar *et al.* (2020) in lactating and non-lactating goat ranged from

59 to 99 µm and 33 to 66 µm respectively. The average of it was  $75.37 \pm 1.34$  and  $47.90 \pm 1.67$  µm. The average values of diameter of intra-lobular duct showed significant difference between lactating and non-lactating stages.

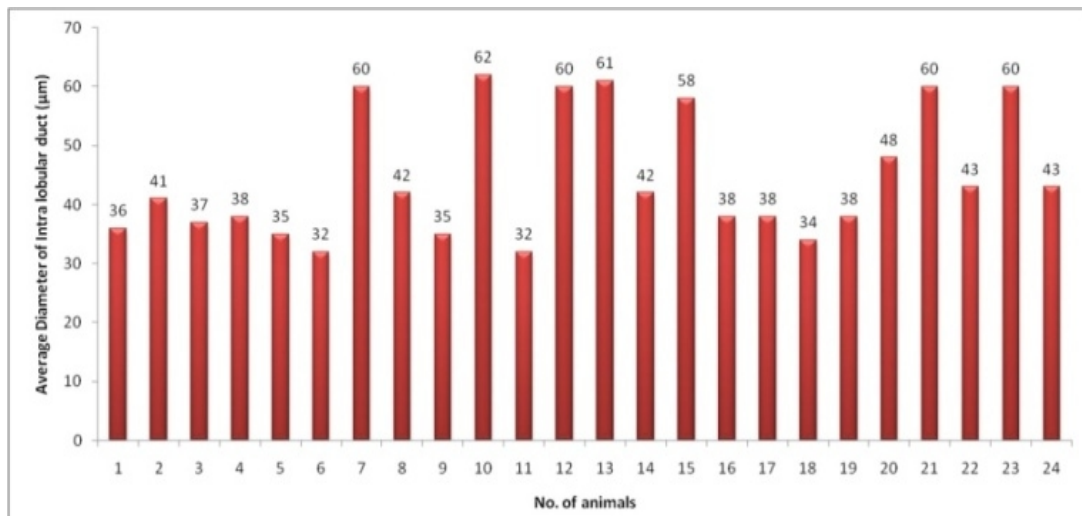


Fig. 9. Showing average diameter of intra-lobular duct (µm).

## CONCLUSION

Significant differences were observed in diameter of alveoli, diameter of lobule, number of alveoli per lobule, diameter of alveolar, height of alveolar epithelium, width of alveolar epithelium, diameter of nuclei, diameter of inter-lobular duct and diameter of intra-lobular duct. The average values of diameter of these parameters showed significant difference between lactating and non-lactating stages.

**Acknowledgement.** The authors are thankful to Dean, College of Veterinary Science and Animal Husbandry, ANDUAT, Kumarganj, Ayodhya for the facilities and cooperation provided.

**Conflict of Interest.** None.

## REFERENCES

- Bancroft, J. D. and Gamble, M. (2003). Theory and Practice of Histological Technique. 5<sup>th</sup> edn., Churchill and Livingstone, New York.
- Bhatia, S. K. and Sahai, R. (1979). Histomorphology of the mammary glands of water buffalo (*Babulus bubalis*) of murrh breed. *Ind. J. Zootomy*, 20: 103-106.
- Culling, C. F. A. (1974). Handbook of histochemical technique, 3<sup>rd</sup> edition, Butterworths & Co. Ltd. Pp: 302.
- Dyce, K. M., Sack, W. O. and Wensing, C. J. G. (2002). In "Text book of Veterinary Anatomy". 3<sup>rd</sup> Edn. W. B. Saunders Company, Philadelphia. Pp: 723-731.
- Fransdon, D. R., Wilke, W. L. and Fails, A. D. (2009). Anatomy and physiology of farm animals. Edn. 7<sup>th</sup>, Pp: 449-456.
- Humason, G. L. (1979). Animal Tissue Techniques. 2<sup>nd</sup> edn., W.H. Freeman Co., London
- Jacobson, N. L. (2000). The mammary gland and lactation. In Duke, s Physiology of Domestic Animals. Reprint of 9<sup>th</sup> Edn. CBS. New Delhi. India. Pp: 842-850.
- Jindal S. K. (1984). In "Goat Production". A Falcon Book from Cosmo Publications.
- Kannan, T. A., Gnanadevi, R., Senthilkumar, S. and Ramesh, G. (2019). Histomorphometric and immunohistochemical details of hemal nodes in Indian buffalo. *Journal of Entomology and Zoology Studies*, 7: 384-387.
- Kausar R., Sarwar, A. and Hayat, C. S. (2001a). Gross and Microscopic Anatomy of Mammary Gland of Dromedaries under different Physiological condition. *Pakistan Vet. J.*, 21(4): 201.
- Lerias, J. R., Hernandez-Castellano, L. E., Suarez-Trujillo, A., Castro, N., Poulis, A. and Almeida, A. M. (2014). The mammary gland in small ruminants: major morphological and functional events underlying milk production-a review. *Journal of Dairy Research*, 81(3): 304-318.
- Luna, L. G. (1968). Manual of histologic methods of the Armed Forces Institute of Pathology (3rd ed.) (pp. 32-217). McGraw Hill Book Company.
- Mahdi, A. A. (2009). Anatomical with Histological structures of the Mammary gland in small ruminants. *Turk. J. Vet Anim. Sci.*, 29: 75-81.
- Mehta H. H., Patel, A. K., Nandasana, K. N., Ramani, U. V., Koringa, P. G., R. G. Shah (2013). The effect of hormone treatment on dry Surti buffalo mammary gland. *International Journal of Pharma and Bio Sciences*, 4(1B): 298-308.
- Mohanty, M., Das, B. C. and Nanda, B. C. (2020). Economic impact of goat farming on livelihood of goat farmers of Nabarangpur district of Odisha, India. *International Journal of Current Microbiology and Applied Sciences*, 9(1): 176-179.
- Naik, G. S. (2015). Gross and Histomorphological studies on the mammary gland of Malnad Gidda cows in Karnataka. Thesis submitted to Department of Veterinary Anatomy and Histology Veterinary College, Bangalore Karnataka Veterinary, Animal and Fisheries Sciences University, Bidar.
- Paramasivan, S, and Geetha, R. (2014). Histology of mammary gland during lactating and non-lactating phases of madras red sheep with special reference to involution *International Journal Science, Environment and Technology*, 5(3): 991-996.
- Senthilkumar, S., Kannan, T. A., Gnanadevi, R., Ramesh, G. and Sumathi, D. (2020). Gross morphological and histomorphometric observations of udder in boer local she-goats. *International Journal of Current Microbiology and Applied Sciences*, 9(1): 445-451.
- Sharma, S. and Rathore, R. S. (2022). Knowledge of beneficiaries and non-beneficiaries about recommended goat farming practices under Attracting and Retaining Youth in Agriculture (ARYA) project. *Biological Forum-An International Journal*, 14(1): 259-263.
- Shivprasad, M. S. (2018). Comparative histomorphological and ultra-structural studies of mammary gland in sheep (*Ovisaries*) and goat (*Capra hircus*). M.V.Sc. Thesis submitted to Maharashtra Animal & Fishery Science University, Nagpur, India.
- Singh, U. B. and Sulochana, S. A. (1997). Handbook of histological and histochemical technique. Premier publishing house Hyderabad. Pp: 8-57.
- Sulochana, S., Singh, Y. and Sharma, D. N. (1981a). Histological studies on the development of mammary gland parenchyma in pregnant sheep. *Ind. J. Vet. Anat.*, 1: 33-38.

**How to cite this article:** Nripendra Singh, Mukesh Kumar, Krishna Nand Singh, Debaish Niyogi, Rakesh Kumar Gupta and Amit Singh Visen and Kabir Alam (2022). Histomorphometric Studies on Mammary Gland of Barbari Goat in Eastern Uttar Pradesh. *Biological Forum – An International Journal*, 14(4): 772-778.